

دانشگاه علوم پزشکی
خدمات بهداشتی درمانی تبریز



مرکز آموزشی، درمانی و تحقیقاتی امام رضا (ع)
Imam Reza Medical Research & Training Hospital
Tabriz - Iran

Current Approaches to Thoracic Traumas In Emergency Department

Seyed Ziaeddin Rasihashemi

Associate Professor of General Thoracic Surgery

Department of Cardiothoracic Surgery

Imam Reza Hospital

Tabriz University of Medical Sciences

۲۰۲۱

Introduction

- Thoracic traumas are the leading cause of mortality after cranial and vertebral traumas.
- The leading cause :traffic accidents, assault and falls from height
- Of all blunt thoracic traumas:
 - Isolated thoracic traumas : 15%
 - Multi-organ traumas: 75%
- The mortality rate: 2–5% in all thoracic traumas
- If accompanied by multi-system injuries: 35%

- ***The consequences of blunt thoracic traumas:***
- Simple rib fractures to more severe conditions
- Multiple displaced rib fractures → causing flail chest
- Tracheal & bronchial ruptures
- Cardiovascular ruptures.

- *Compared with blunt thoracic traumas, penetrating thoracic traumas: less common.*
- Gunshot injuries :5% of all thoracic traumas
- Sharp object injuries :37% of cases

- *The most significant cause of mortality:*
cardiac and major vessel injuries
- *The first assessment:*
checking the circulation and airways.

- For the monitoring of trauma patients in emergency clinics it is important to retain:
 - Ultrasound and X-ray,
 - Electrocardiogram (ECG)
 - Echocardiography (ECHO) .

- *Previous studies have shown that bedside ultrasonography provides more specific and reliable data than physical examinations in assessments of pleural fluid and pneumothorax at the time of initial evaluation when a patient presents to the emergency unit with thoracic trauma*

Primary approaches in patients with thoracic trauma

- In recent years, trauma patients in emergency clinics have usually been treated in line with the Advanced life support (ATLS = Advanced Trauma Life Support) protocol.
- ***Classified into:***
 - Primary care
 - Secondary care

- ***Primary care: “ABCDE”***
- (A) ensuring airway flow and fixation of the neck vertebra
- (B) evaluation of the respiratory system
- (C) circulatory system
- (D) consciousness
- (E) total body evaluation

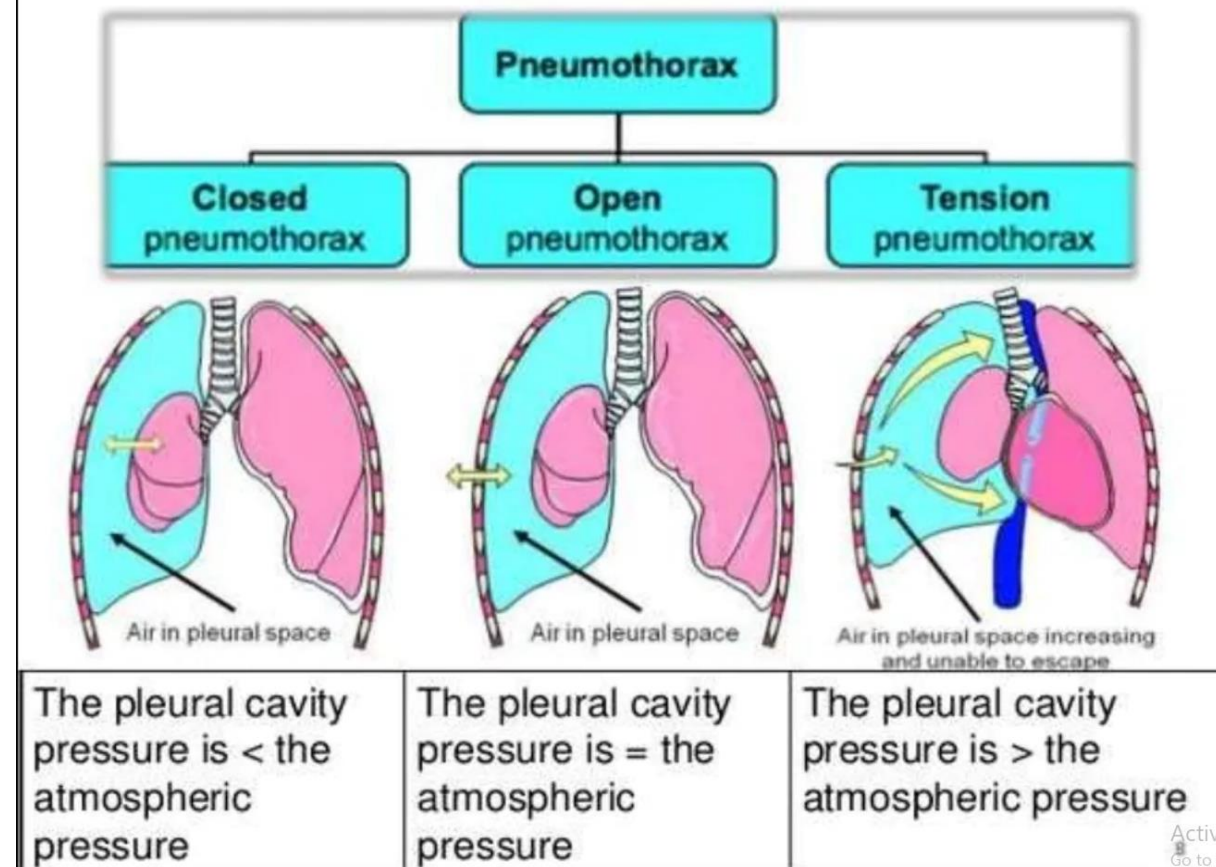
Secondary evaluation of life-threatening thoracic trauma

- All body parts of the trauma patients should be evaluated with:
- physical examination,
- ultrasonography
- radiological investigations
- (such as CXR, vertebra, pelvis, extremities, CT and MRI, if needed), as required

- Patients with thoracic traumas are evaluated according to the ATLS protocol.
- ***Six potentially morbid conditions:***
- Massive hemothorax
- Tension pneumothorax
- Open pneumothorax,
- Flail chest
- Cardiac tamponade
- Air embolism and respiratory obstruction

Traumatic pneumothorax

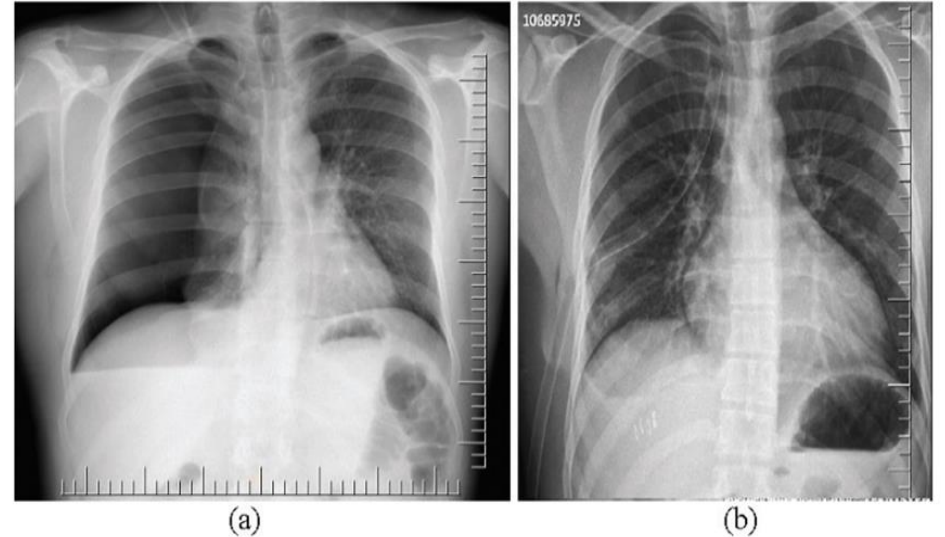
- Air from the atmosphere or lung parenchyma enters the pleural space following blunt or penetrating trauma.
- *Causes:*
- Rib fractures.
- Bulla or blebs that may already be present in the lungs
- Tracheal or bronchi injury



- **Traumatic pneumothoraxes are classified into three groups**
 - Simple(closed)
 - Open
 - Tension pneumothorax

Simple pneumothorax

- Secondary to rib fractures.
- Major symptoms:
 - Pain and dyspnea
 - Decreased respiratory sounds at the side of pneumothorax.
- Chest radiography.....
- Monitor such cases under nasal oxygen therapy
- Tube thoracostomy must be performed in moderate or advanced cases of pneumothorax

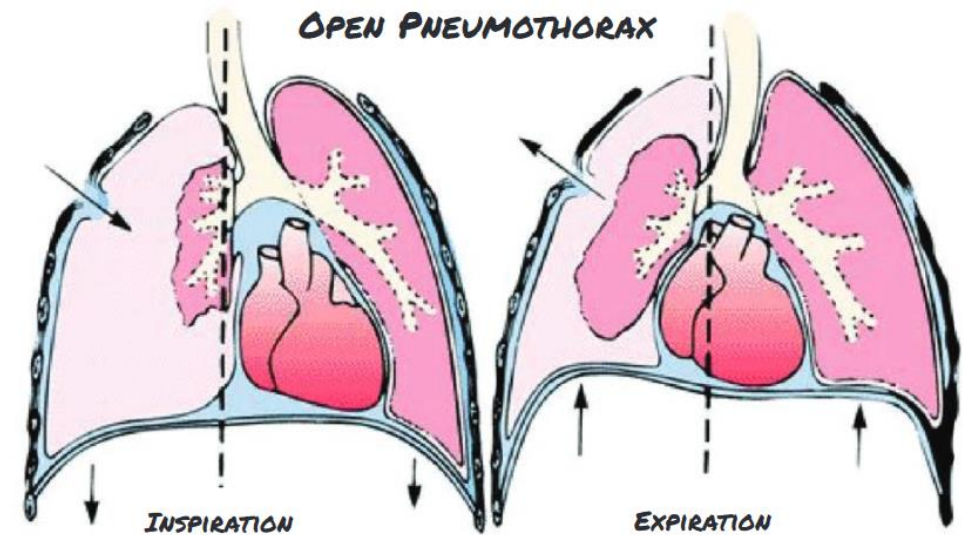


In patients connected to mechanical ventilators, a tube thoracostomy should not be delayed in these patients

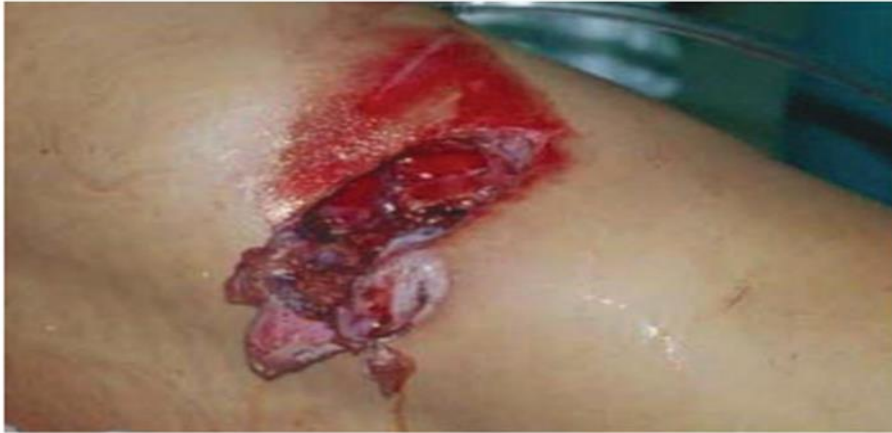Open pneumothorax

Infiltration of positive pressure atmospheric air into the pleural space after an injury to the thoracic wall and parietal pleura

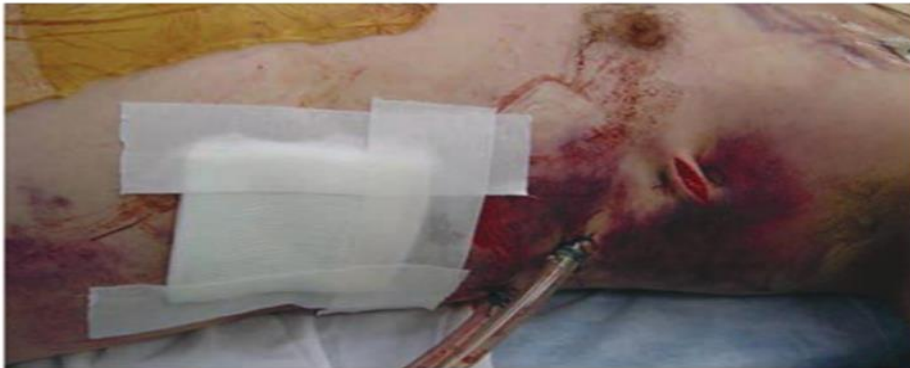- Life-threatening condition that requires emergency intervention.
- In each inspiration of the patient, air enters into the pleural space through the open region on the thoracic wall.
- In the event of the defect being larger than 0.75-times the tracheal diameter, air enters through the defect instead of the trachea.



pushes the heart and major vessels, and the mediastinum to the opposite side



A



B

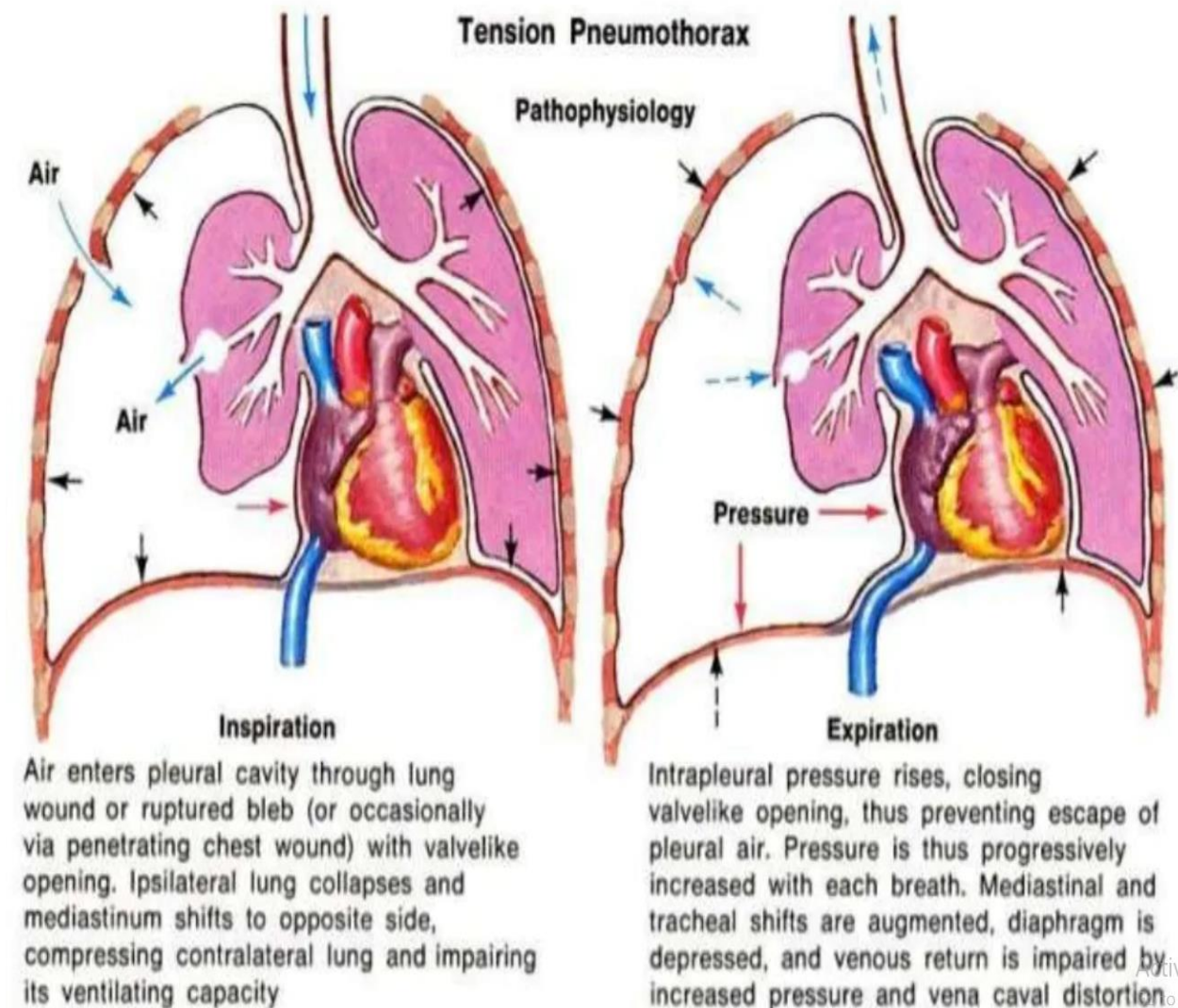
Figure 7-4. A. Full-thickness loss of the chest wall results in an open pneumothorax. B. The defect is temporarily managed with an occlusive dressing that is taped on three sides, which allows accumulated air to escape from the pleural space and thus prevents a tension pneumothorax. Repair of the chest wall defect and tube thoracostomy remote from the wound is definitive treatment.

- Hypoxia,
 - Asphyxia,
 - Respiratory acidosis and decreased cardiac output.
 - Torsion of the vena cava inferior and superior also occurs. Cardiac output decreases and the patient may go into cardiac arrest.
- ***The first intervention :***
 - closure of the terminal end of the open defect on the thoracic wall in such a way to that the entry and exit of air is prevented.
 - Alternatively, the pneumothorax could be totally closed, and the patient could be monitored following a tube thoracostomy

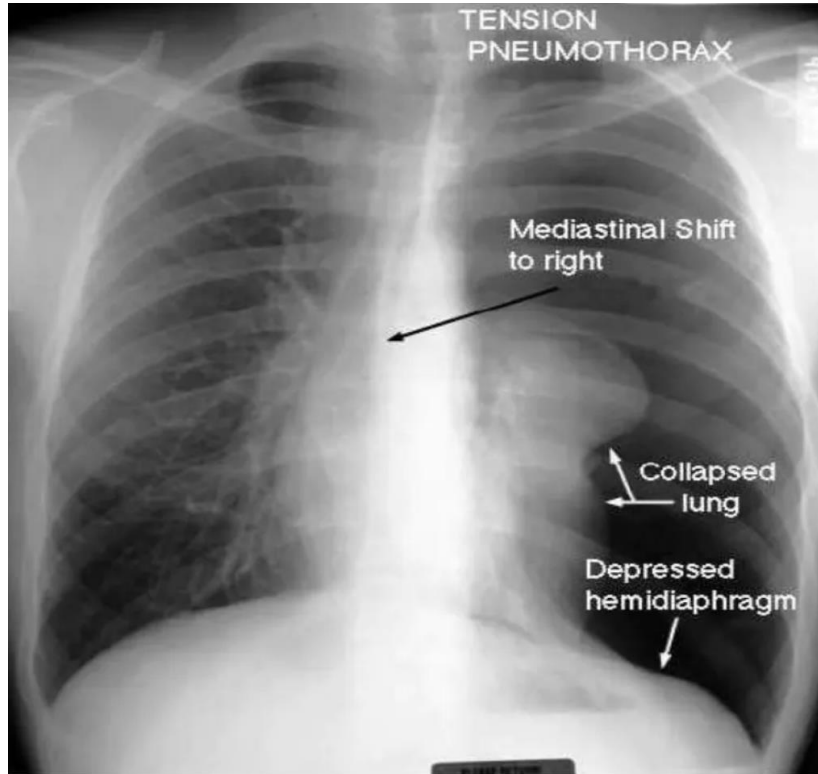
Tension pneumothorax

- There is one-way air entry into the pleural space increased air pressure within the pleural space puts pressure on the lung and pushes the mediastinum to the opposite side....applies pressure on the other lung.
- Pushing the mediastinum along with the heart and other vascular structures towards the opposite thoracic space is called “mediastinal shift”.

Injury to the visceral pleural sheet
Injury to the trachea or bronchi



- ***Mediastinal shift:***



- Impairs cardiac venous filling
- Life-threatening condition,
- Dyspnea, tachypnea, hypoxia, tachycardia, hypotension and agitation
- In the absence of an emergency diagnosis and tube thoracostomy: metabolic acidosis, decreased cardiac output, cardiac arrest or even death

Emergency intervention:

Empty the air in the pleural space and reducing the pressure on the lungs and vital organs

A thoracentesis :

between the midclavicular line and the 2nd intercostal space to empty the air from the intrapleural space, thus.

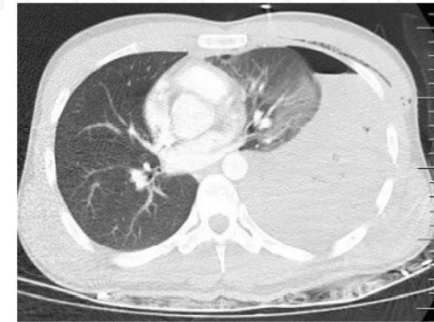
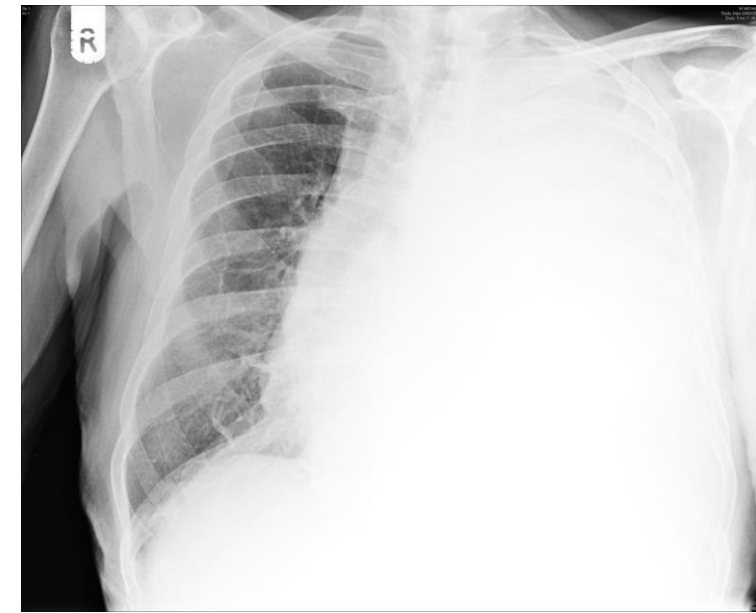
A tube thoracotomy should be performed as soon as possible

Traumatic hemothorax

Deposition of blood between the pleural membranes, and is most frequently caused by trauma.

Originate from thoracic wall, lungs, blood vessels, mediastinum or diaphragm

- ***Blunt thoracic injuries:***
- Result of the bleeding of the pleura or the lung parenchyma,
- Secondary to rib fractures
- In structures with high blood flow, such as the heart, aorta, pulmonary artery, and vena cava inferior and superior,
- ***may very quickly become mortal***



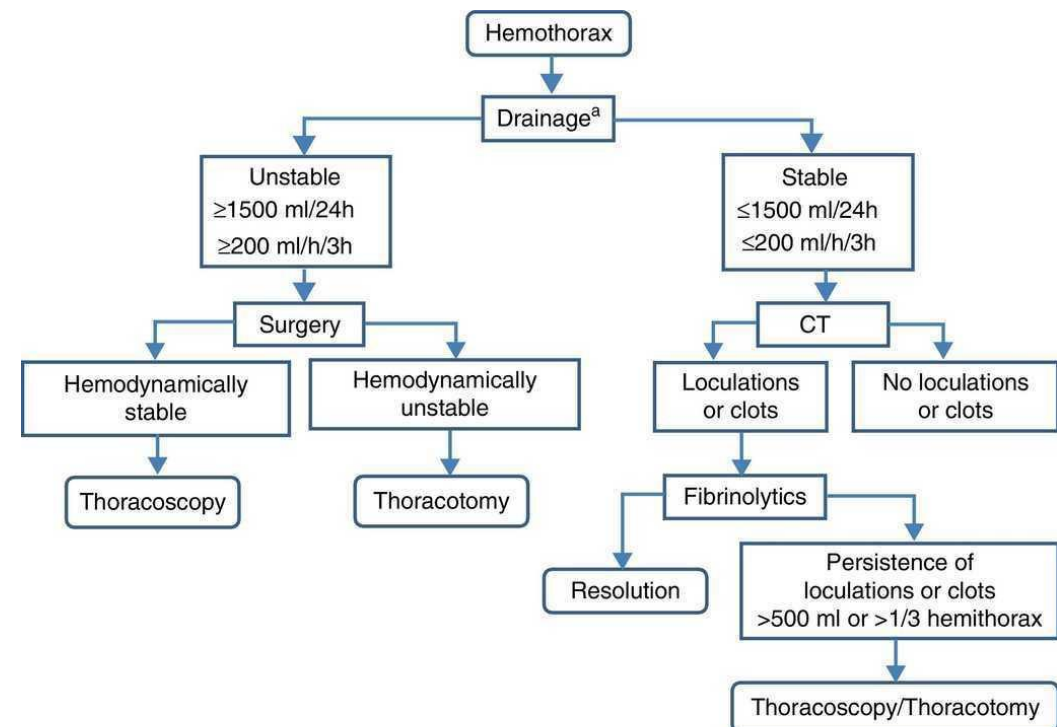
While bleeding of up to 500–750 mL:
Can be tolerated

- **Bleeding above 1500 mL:**
- Signs of shock

- **Diagnosis:**

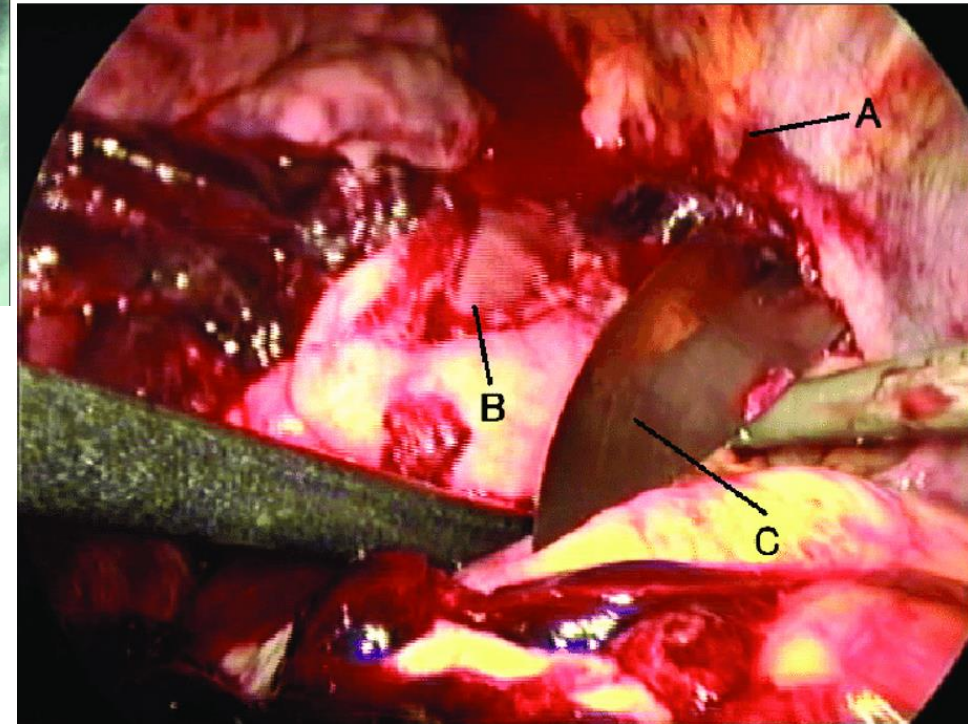
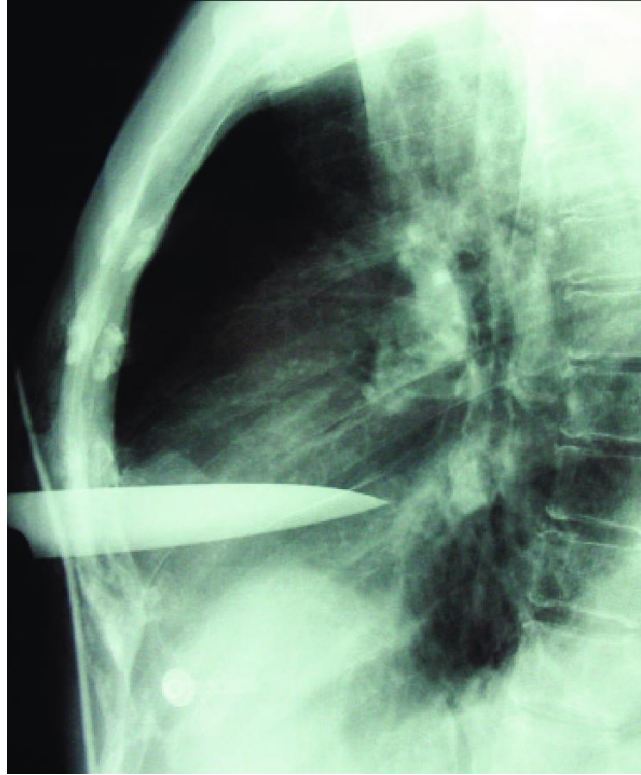
- CXR and thoracentesis
- Thoracic CT is more specific for the diagnosis of hemothorax
- **Recently, in emergency clinics, bedside USI has also frequently been used for the diagnosis of hemothorax**

- **Bleeding of 750– 1500 mL :**
- Can result in the development of tachycardia and hypotension



- ***Penetrating traumas:***

- Most frequently caused by intercostal artery & internal mammarian artery injuries
- May require thoracotomies



For hemorrhagic shock:

Emergency thoracotomies

Applying finger pressure to the bleeding artery rapidly improve the patient's vital signs

Emergency thoracotomy indications in hemothorax

- Drainage ≥ 1500 mL after initial tube thoracostomy,
- 200 mL/h drainage during the first 2–4 h of follow-up
- 100 mL/h drainage during the first 6–8 h of follow-up
- ≥ 1500 mL/day drainage during the first 24 h
- Progression of shock despite treatment

Tube thoracostomy

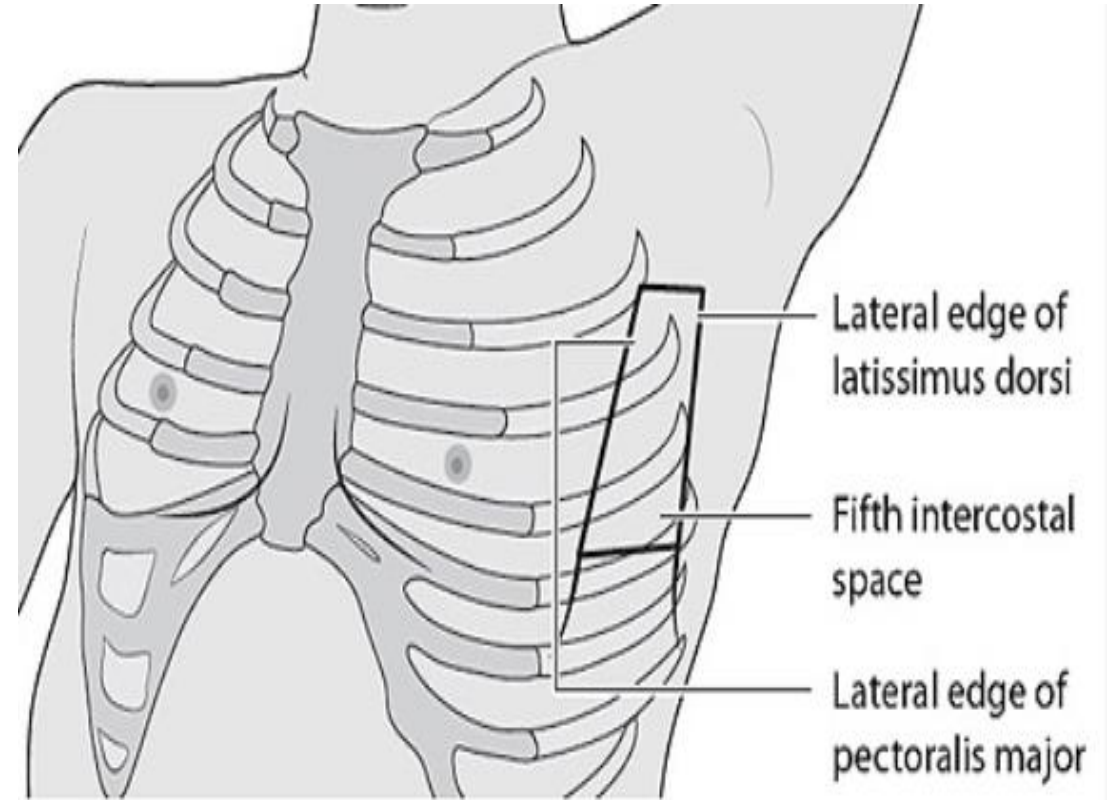
- ***Treatment of***
- Traumatic pneumothorax and/or hemothorax
- Essential surgical intervention in cases requiring drainage of the pleural cavity in patients suffering a chest trauma

Tube thoracostomy

Treatment of

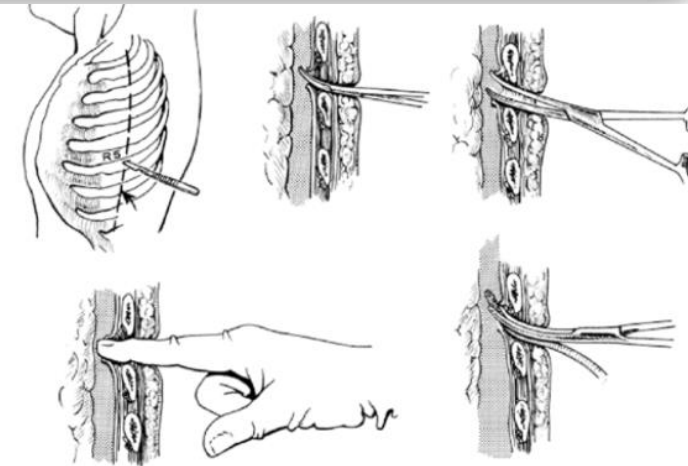
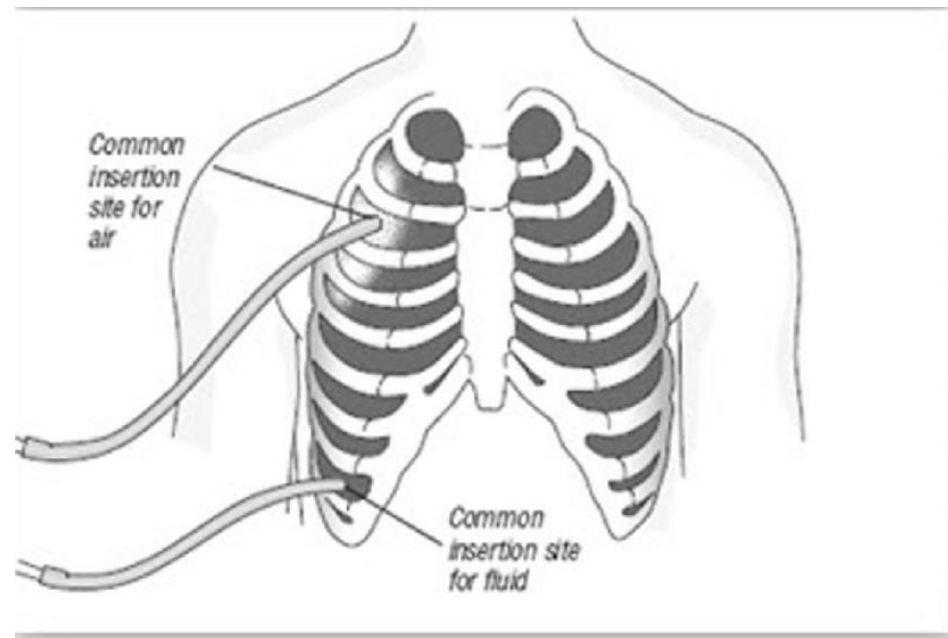
Traumatic pneumothorax and/or hemothorax

- Essential surgical intervention in cases requiring drainage of the pleural cavity in patients suffering a chest trauma



Indications

- Pneumothorax of more than 10%
- Radiologically-confirmed hemothorax.
- Intensive care patients with severe chest traumas who require mechanical ventilation, even if there is no apparent pneumothorax and/or hemothorax



A patient with penetrating or blunt chest trauma

Who transferred to the emergency unit whose vitals are completely lost, or about to be lost

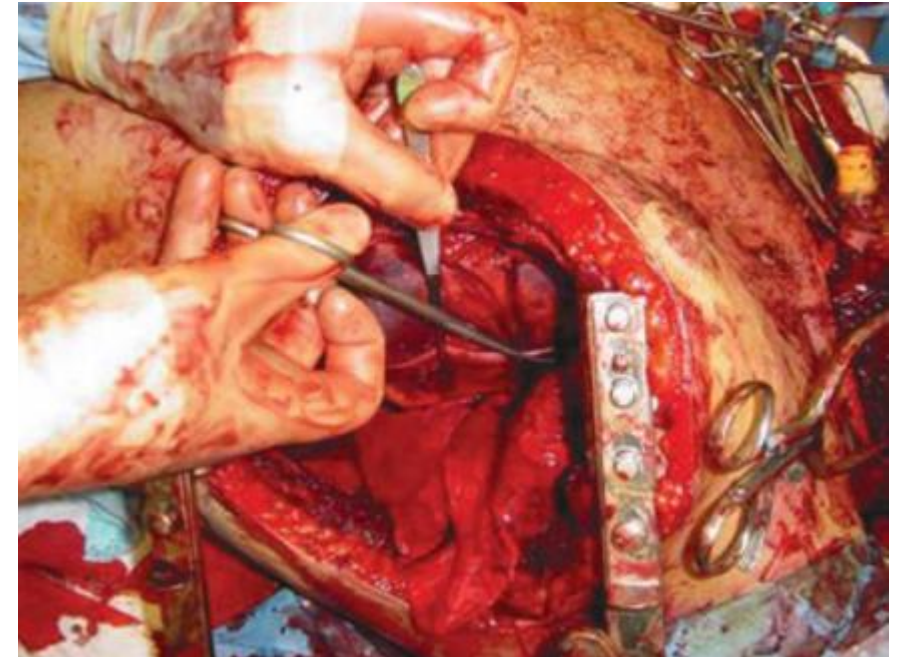
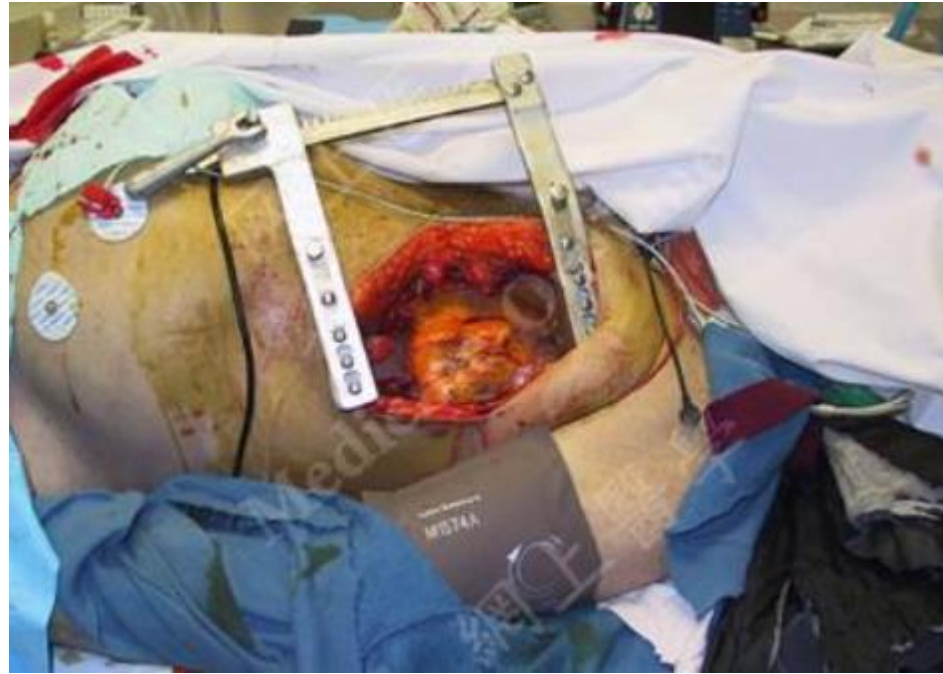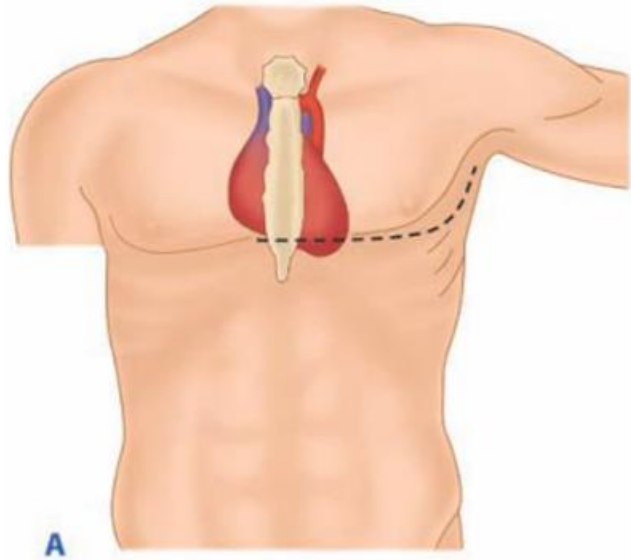
It would not be erroneous to perform an emergency bilateral tube thoracostomy

A view of chest tube insertion (the main steps of chest tube insertion).

Note

- The chest tube should never be clamped for any reason while the patient is being transported or transferred outside the emergency unit.
- The tube thoracostomy is removed under the control of a lung radiography after the air leakage stops or drainage drops below 100 mL/day

Emergency care thoracotomy

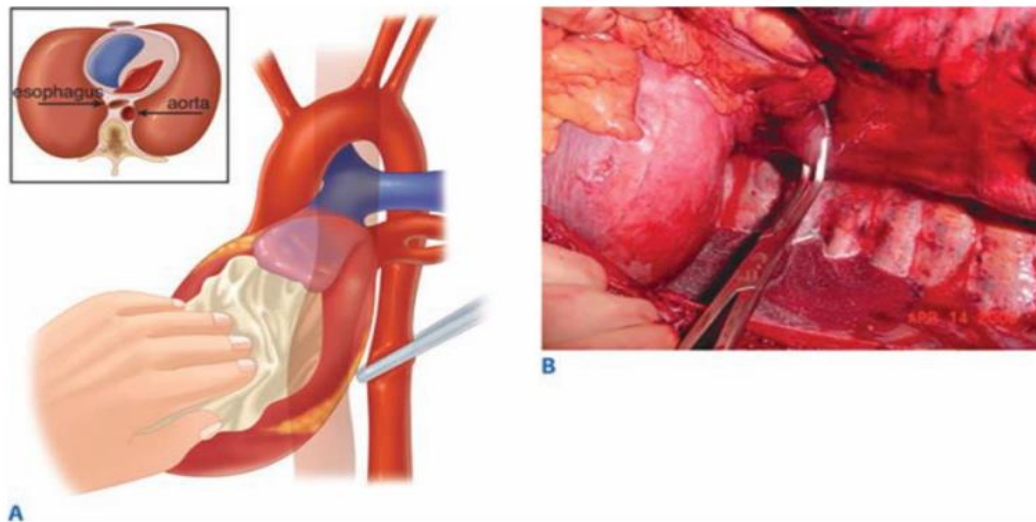


Life-saving procedures for a limited patient group

The rate of survival between 0 and 64%, with the best outcomes achieved for isolated penetrating cardiac injuries. Blunt and multiple trauma: 1 and 3%

- ***The reasons for an emergency care thoracotomy :***

- Drainage of the pericardial tamponade,
- Control of intrathoracic or cardiac bleeding,
- Control of massive bronchovenous air embolisms& bronchopleural fistula,
- Open cardiopulmonary resuscitation
- Temporary occlusion of the descending thoracic aorta (cross clamp placement)



- ***Contraindications for emergency care thoracotomy :***

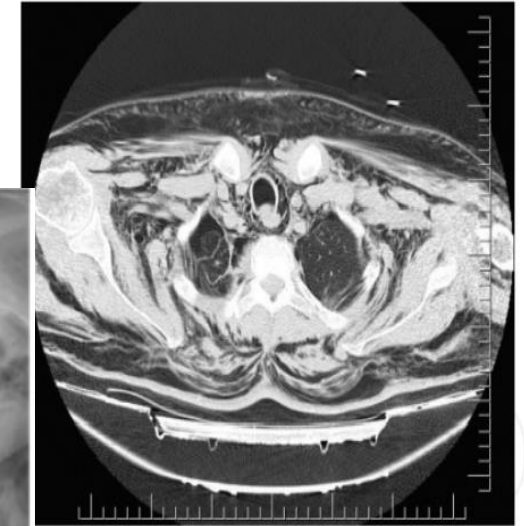
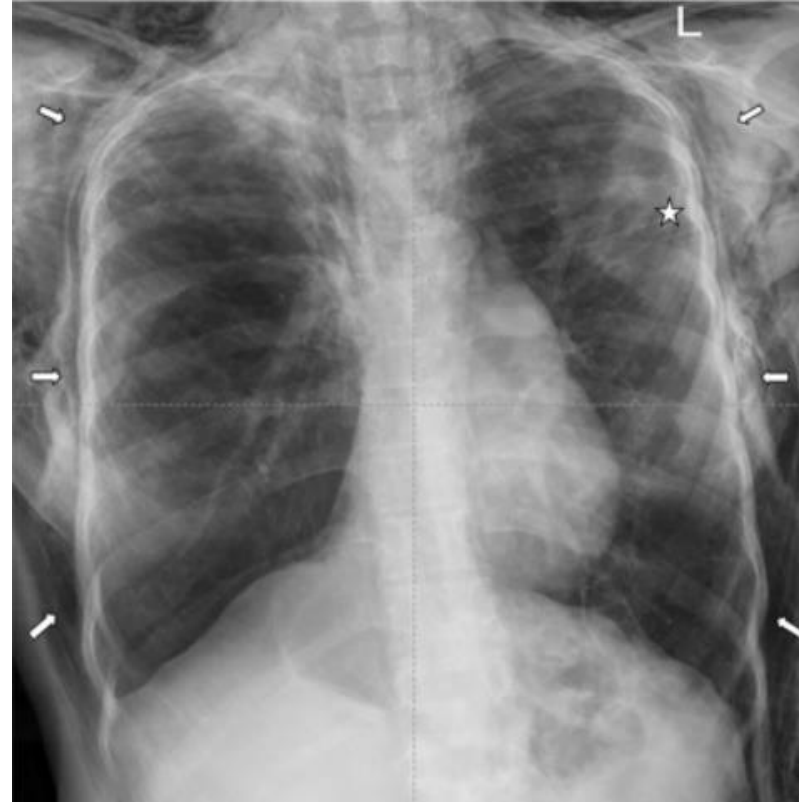- Cardiopulmonary resuscitation lasting longer than 15 minutes for penetrating chest traumas,
- Cardiopulmonary resuscitation lasting longer than 5 minutes for blunt chest traumas,
- Non-traumatic arrest,
- Severe head trauma,
- Severe multi-system injuries,
- The absence of appropriately trained staff and insufficient equipment.

Indications of emergency care thoracotomy.

- Prehospital cardiopulmonary resuscitation that lasts less than 15 min in patients exposed to penetrating trauma
- Prehospital cardiopulmonary resuscitation that lasts less than 5 min in patients exposed to blunt trauma
- Serious continuous systolic hypotension after injury (≤ 60 mmHg) caused by:
 - Cardiac tamponade
 - Bleeding (intrathoracic, intraabdominal, extremity, cervical)
 - Air embolism

Subcutaneous emphysema

- ***Entry of air into the subcutaneous soft tissue of the thoracic wall***
- Crepitations during palpation,
- Visualization of air in the subcutaneous tissue and between the muscles in a lung radiography.
- Swelling of the head, neck and face, and while there is
- ***No specific treatment for subcutaneous emphysema,***



To reduce subcutaneous emphysema

air drainage can be performed by injecting a few large lumen wide-diameter catheters subcutaneously and between the muscles of the anterior thoracic wall

Contusion and hematoma of the thoracic wall

- ***Bleeding following:***
- Rib fractures
- Tearing of the thoracic wall muscles.
- More common in the elderly.
- Conservative treatment methods and blood transfusions, if required

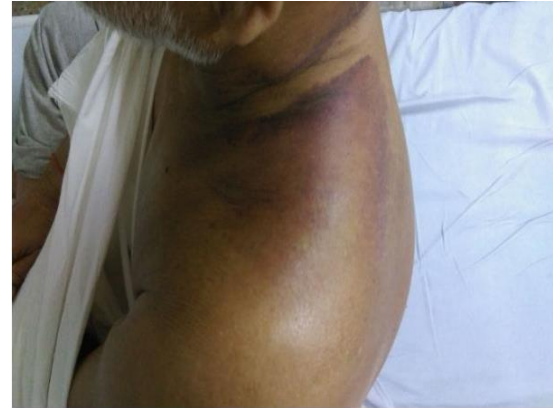

Fig. 1.

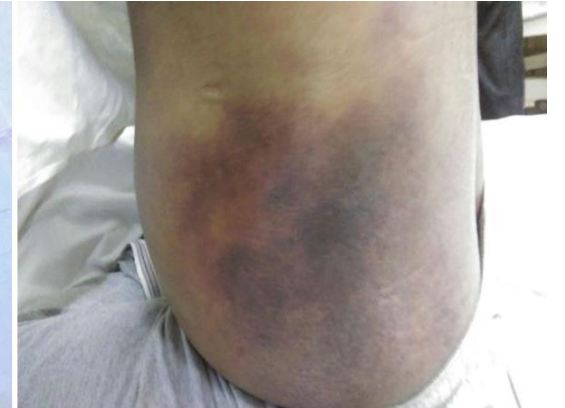

Fig. 2.

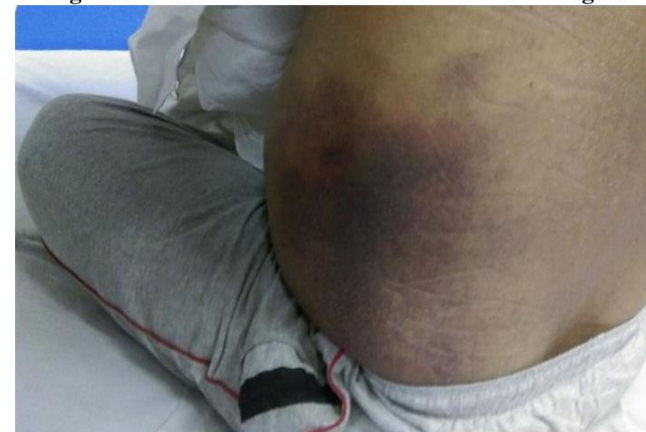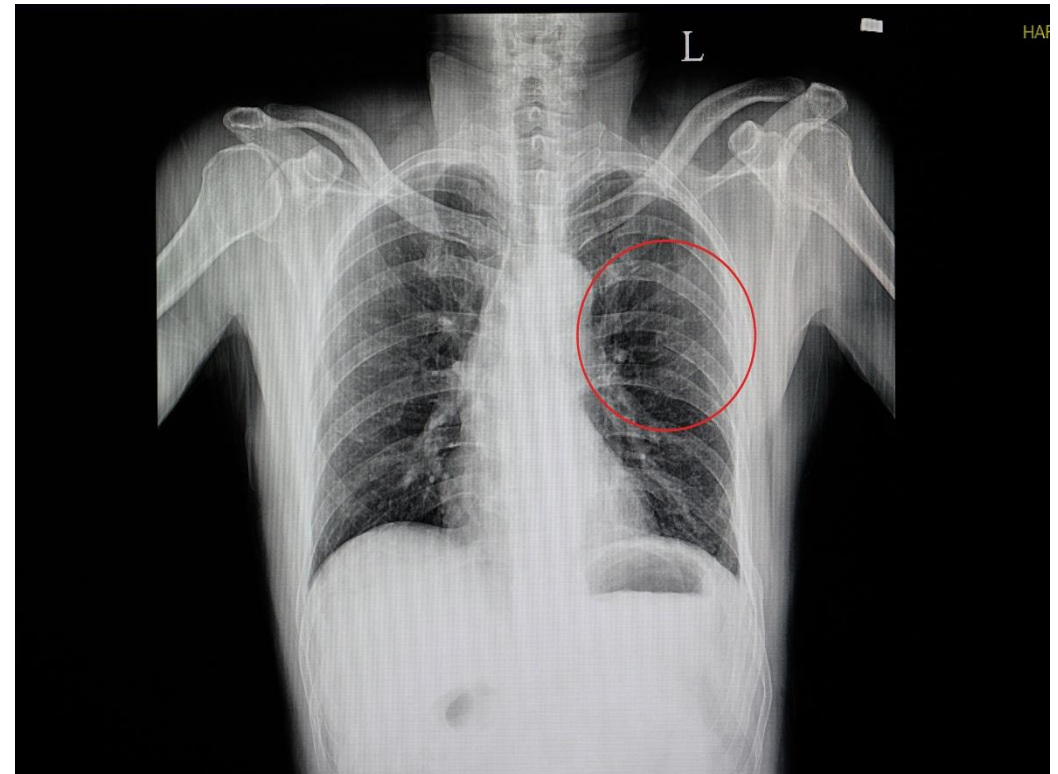


Fig. 3.

Rib fractures

- 35–40% of all thoracic trauma cases, is rib fracture
- More frequent in the elderly
- Mostly encountered along 4–9 and the middle axillary line
- *Fractures of the first and second ribs are generally rare*
- *may be broken due to very high-energy trauma*
- *accompanied by subclavian vessel and brachial plexus injuries.*
- Rib fractures may be accompanied by lung, bronchus or cardiac injuries
- *In the presence of 9th–12th rib fractures:*
- Organ injuries, such as the liver and spleen

- *Trauma to the anterior thoracic wall:*
- Result in costochondral detachment
- More painful condition
- Requires a longer duration of treatment



- ***Half of all rib fractures:***
- Unnoticed in CXR
- Chest CT is more specific for their diagnosis

- ***Early-term complications of rib fractures:***
- Pneumothorax and hemothorax

- ***Late-term complications :***
- Atelectasis and pneumonia

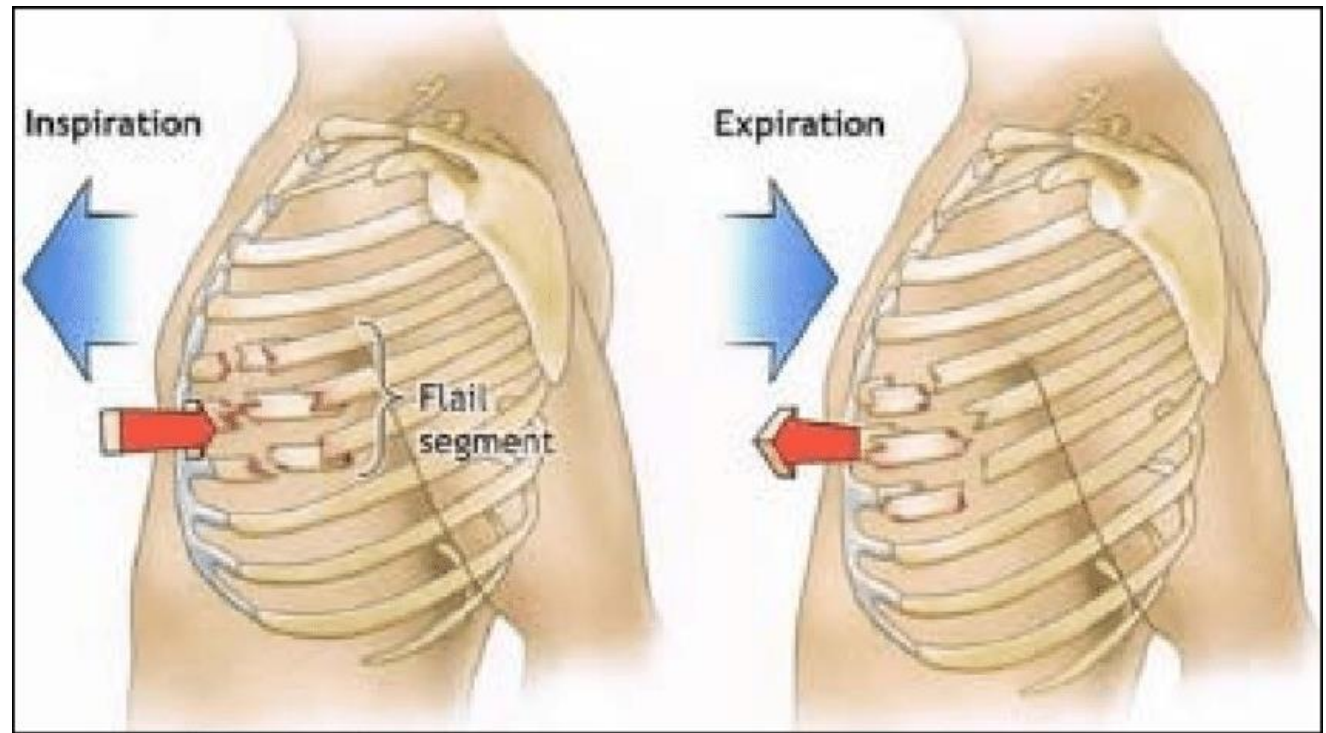
- *A tube thoracostomy is inevitable in the presence of hemothorax and pneumothorax*
- ***Surgical fixation becomes necessary :***
- When the fractured tips are displaced
- When there are fractures to more than one consecutive rib

Flail chest

- ***Fracture of two or more consecutive ribs***
- Paradoxical respiration of the thoracic wall in at least two places
- Impairs hemodynamics, developing mediastinal shift, decreased cardiac output, hypotension, Syncope and sudden cardiac arrest.
- ***The rate of mortality :10 and 15%***
- ***The most common causes:***
- Massive hemothorax, lung contusion ,ARDS
- ***Rib fixation is preferred:***
- Patients who stay in intensive care for long periods of time
- Who cannot tolerate other interventions
- Who need thoracotomies due to morbidity.

Flail chest

- ***Fracture of two or more consecutive ribs***
- Paradoxical respiration of the thoracic wall in at least two places
- Impairs hemodynamics, developing mediastinal shift, decreased cardiac output, hypotension, Syncope and sudden cardiac arrest.
- ***The rate of mortality :10 and 15%***
- ***The most common causes:***
- Massive hemothorax, ung contusion ,ARDS



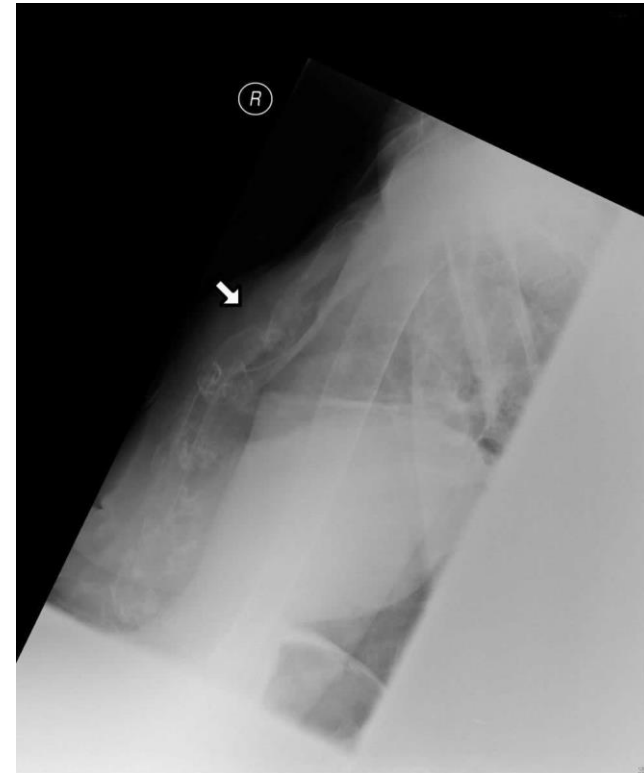- ***Rib fixation is preferred:***
- Patients who stay in intensive care for long periods of time
- Who cannot tolerate other interventions
- Who need thoracotomies due to morbidity.

Sternum fractures

- Occur during in-vehicle traffic accidents,
- Particularly in the elderly and in front-seat passengers
- Transverse fractures
- At the point of junction between the manubrium and corpus sterni & at the corpus sterni

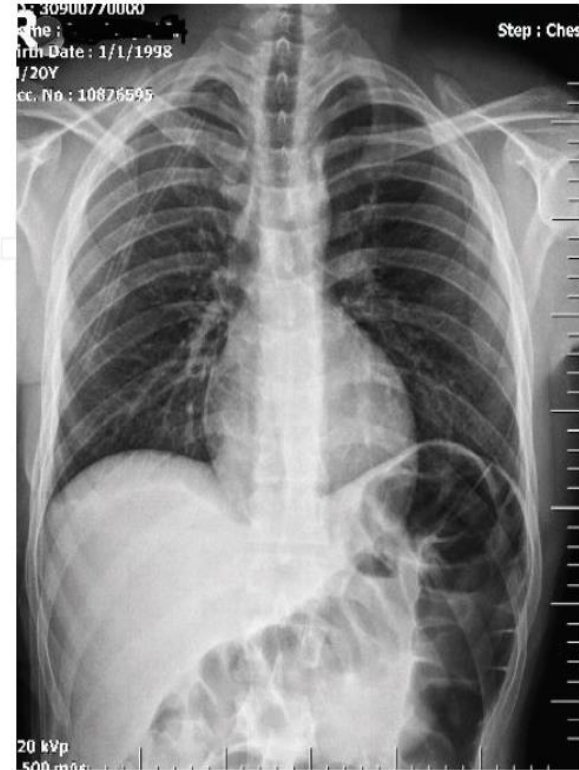- ***Lateral radiography***
- ***Thoracic CT***

- Patients should be hospitalized
- Closely monitored with ECHO and ECG assessments



Clavicle fractures

- More common since the use of seatbelts in vehicles
- In the 1/3rd middle part of the clavicle



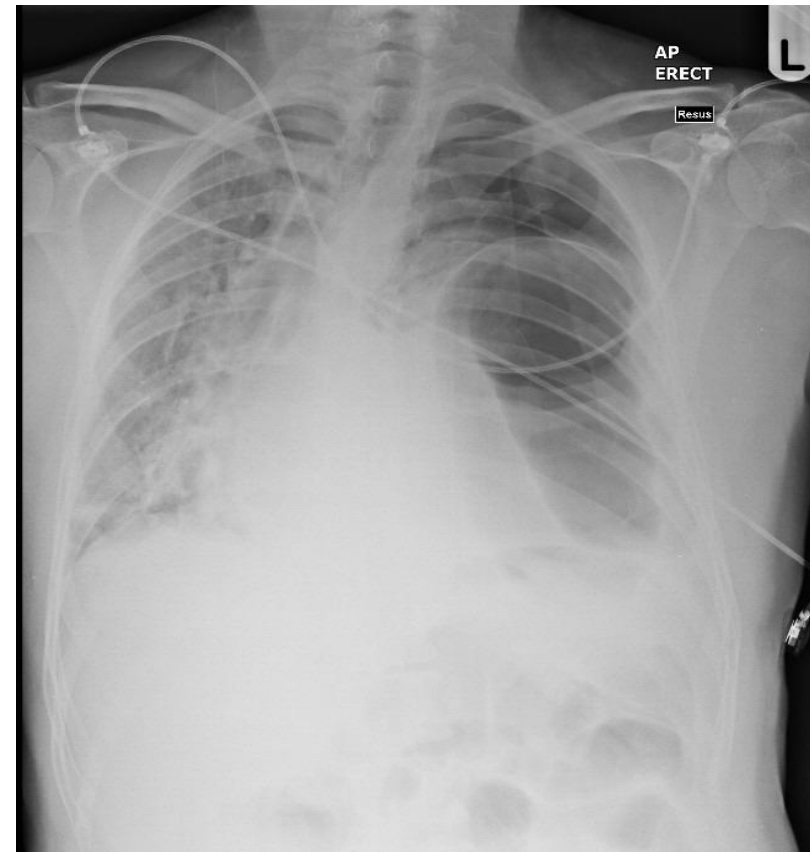
Scapula fractures

- A thick bone and is well-protected by the muscles in the chest wall
- Only develop as a result of high-energy trauma.
- CXR
- Thoracic CT
- May be accompanied by brachial plexus injuries.

Traumatic diaphragm injuries

- ***Conventional radiological investigations:***
- when the patient is *stabilized* are the most important diagnostic methods.
- Diaphragm elevations
- Basal atelectasis
- Loss and/ or irregularity of diaphragm borders,
- Blunting of the costophrenic sinus
- Abnormal nasogastric tube positioning
- ***Fluoroscopy can indicate whether or not the diaphragm is immobile, or can display paradoxical movements***

- 75% are associated with blunt traumas,
- 25% are due to penetrating traumas.
- Five times more common on the left side than on the right side



- CT is also important for the identification of concomitant injuries, such as those to the liver, spleen or kidneys.
- The CT findings:
- The interruption of diaphragm continuity,
- Visualization of a defect in organs into thoracic cavity,
- Abnormal positioning of the nasogastric tube,
- Direct contact of the posterior of the ribs with such organs as the liver and stomach,
- Injuries that progress from one side of the diaphragm towards the other side

CT is also important for the identification of concomitant injuries, such as those to the liver, spleen or kidneys.

- The CT findings:
- The interruption of diaphragm continuity,
- Visualization of a defect in organs into thoracic cavity,
- Abnormal positioning of the nasogastric tube,
- Direct contact of the posterior of the ribs with such organs as the liver and stomach,
- Injuries that progress from one side of the diaphragm towards the other side

